

УЧЕБНИК

Н.В. Мерзликин, Н.А. Бражникова,
Б.И. Альперович, В.Ф. Цхай

ХИРУРГИЧЕСКИЕ БОЛЕЗНИ

В двух томах

Том II

Рекомендовано ГОУ ВПО «Московская медицинская академия им. И.М. Сеченова»
в качестве учебника для студентов учреждений высшего профессионального
образования, обучающихся по специальности 060101.65 «Лечебное дело»
по дисциплине «Хирургические болезни»

CONTENTS

Chapter 1. External Hernias of the Abdominal Wall	7
General herniology. Hernia complications	7
Herniology.	22
Chapter 2. Diseases of the Stomach and Duodenum	41
Surgery for peptic ulcer diseases	41
Perforated ulcer of the stomach and duodenum (<i>ulcus perforans</i>)	51
Gastroduodenal hemorrhage (<i>haemorrhagia gastroduodenalis</i>)	64
Malignancy of an ulcer. Ulcerative stenosis.	77
Diseases of the operated stomach (<i>morbi ventriculi postoperativa</i>)	85
Chapter 3. Surgical Diseases of the Liver and Biliary Tract	94
Gallstone disease (<i>cholelithiasis</i>)	94
Choledocholithiasis and stenosis of the major duodenal papilla (<i>choledocholithiasis et stenosis papillae duodeni major</i>).	111
Acute cholecystitis (<i>cholecystitis acuta</i>)	123
Post-cholecystectomy syndrome (<i>syndromum postcholecystectomicum</i>)	140
Parasitic liver diseases (<i>echinococcosis, alveococcosis</i>)	157
Surgical complications of opisthorchiasis	176
Obstructive jaundice (<i>icterus mechanicus seu obstructivus</i>)	198
Portal hypertension (<i>hypertensio portalis</i>)	214
Chapter 4. Surgical Diseases of the Pancreas	228
Acute pancreatitis (<i>pancreatitis acuta</i>)	228
Chronic pancreatitis (<i>pancreatitis chronica</i>)	249
Chapter 5. Intestinal Diseases	271
Acute appendicitis (<i>appendicitis acuta</i>)	271
Complications of acute appendicitis	286
Acute intestinal obstruction (<i>ileus</i>)	300
Diffuse polyposis of the large intestine (<i>polyposis intestini crassi diffusa</i>)	314
Acute disorders of mesenteric circulation	320
Adhesive disease (<i>morbus adhaesivus</i>)	335

Chapter 6. Diseases of the Rectum and Anorectal Region	352
Hemorrhoids (<i>haemorrhoids</i>).	352
Anal fissure (<i>fissura ani</i>)	364
Rectal prolapse (<i>prolapsus recti</i>)	368
Rectal polyps (<i>polyposes recti</i>)	374
Paraproctitis and fistula of the rectum.	374
Chapter 7. Blunt Abdominal Trauma (<i>Trauma Abdominis Obtusum</i>).	389
Chapter 8. Peritonitis	409
List of Abbreviations	430
References	431

Chapter 2

DISEASES OF THE STOMACH AND DUODENUM

SURGERY FOR PEPTIC ULCER DISEASES

Peptic ulcer of stomach and duodenum is one of the most common diseases. According to WHO, from 5 to 10% of the world's population suffer from it. Moreover, in different countries, the prevalence of the disease is different. It is most frequent in such developed countries as the USA, Great Britain, Germany, etc. The smallest incidence is registered in the countries of Southeast Asia. This fact is probably explained by both genetic factors and nutrition features of the population. According to the literature, the number of patients with peptic ulcer varies from 1.5 to 5%. According to Wudvort, about 10% of US residents suffer from peptic ulcer disease. Currently, about 300,000 gastric resections and about 30,000 other operations for peptic ulcer are performed in the world annually. In Russia, about 45,000 gastric resections and 25,000 perforated ulcer suturing surgeries are performed every year. Despite the long history of surgical treatment of peptic ulcer disease (the first operations were done more than a hundred years ago), the effectiveness of various interventions for this disease is still being debated.

Surgical treatment of peptic ulcer was discussed at the XXV, XXIX, and XXX All-Union Congresses of Surgeons, VIII All-Russian Congress of Surgeons and a number of other conferences. The old-fashioned opinion about ulcer treatment is that the therapist is powerless, the surgeon is dangerous, and God is merciful. Currently, the basic principles of surgical treatment of this disease are developed in detail and tested in clinical practice. This is the merit of many surgeons, especially S.I. Spasokukotsky, S.S. Yudin, A.G. Savinykh, V.S. Mayat, Yu.M. Pantsyrev, V.S. Savelyev, and Drakstadt.

Surgical interventions performed for peptic ulcer disease should be primarily of a pathogenetic nature, i.e., they should influence the factors causing the disease and eliminate ulcer in the wall of the stomach or duodenum. The main features of gastric secretion were studied in the laboratory of I.P. Pavlov; secretion occurs in three phases.

The first phase depends on the irritation of the vagus nerve fibers — the secretory nerve of the stomach. It is called a reflex phase. Irritation of the branches of the vagus nerve causes secretion of the gastric glands that produce gastric juice.

The second phase depends on the release of gastrin in the blood, which is produced by the mucosa of the gastric antrum and the first part of the duodenum. The hormone is produced upon contact of food masses with the mucous membrane in these areas. This phase is called hormonal.

The third phase depends on the concentration of enterokinase in the blood, produced by the mucosa of the small intestine upon contact with chyme. The proportion

of phases of gastric secretion varies. In a healthy person, about 1.5 liters of gastric juice is released per day. In this case, the reflex phase of gastric secretion accounts for about 80%, hormonal — for about 15% and intestinal — for about 5%. In case of illness, the phases of daily secretion can vary significantly. Many authors believe that the reflex phase prevails in patients with duodenal ulcer, and the hormonal one — in patients with stomach ulcer. The proportion of the third phase (intestinal) is so small that it can be neglected when substantiating surgical interventions.

According to the literature, only 10% of patients with peptic ulcer develop complications requiring surgical intervention. The rest should be treated with conservative methods. One of the most renowned Russian surgeons Yu.Yu. Janelidze argued that none of the organs gives a person so much pleasure as the stomach. Therefore, it should be removed only for very strict indications. Since the opinions of different authors regarding the indications for surgical treatment are different, we will describe the prevailing opinion.

All indications for surgery are divided into two groups — absolute and relative. Absolute are indications for surgery, when non-performance of the operation is life-threatening.

- 1) perforated ulcer;
- 2) severe gastrointestinal bleeding;
- 3) corrosive pyloric stenosis;
- 4) malignant ulcer or a reasoned suspicion of malignancy.

Perforated ulcer is a formidable complication of peptic ulcer requiring immediate surgery, since in this situation a delay in surgery is fatal. Any type of perforation is life-threatening; exit of the infected contents of the gastrointestinal tube in the abdominal cavity leads to the development of progressive, fatal peritonitis.

Severe gastric bleeding also directly threatens the patient's life. Rapidly increasing anemia and metabolic disorders require immediate surgical treatment to eliminate developing homeostasis disorders that are life-threatening to the patient.

Pyloric stenosis due to cicatricial changes in the pylorus or in the first section of the duodenum also threatens the life of the patient. Slower development of the process (sometimes for months or even years), compared with previous complications, leads to gradual, but inevitable development of high obstruction of the gastrointestinal tract with following chronic dehydration, serious disorders of mineral metabolism (the most serious of which being hypochloremia), loss of acids, and progressive loss of body weight, up to complete exhaustion. A convulsion in the form of chloroprivic tetany can simulate epileptic seizures, which makes it difficult to diagnose the disease in a timely manner. All this leads to the death of the patient, if surgical intervention is not performed to correct the current situation. This complication is most characteristic of duodenal and stomach ulcers.

Malignancy of chronic gastric ulcer is also an absolute indication for surgery. Surgery should be carried out in cases of strong suspicion of malignant degeneration of the ulcer. In any of these situations, an immediate threat to the patient's life due to the progression of the malignant process is beyond doubt. Delayed surgery can be life-threatening, since in some cases the growth of a malignant tumor is rapid and dissemination in the form of distant metastases can exclude the possibility of radical care for the patient.

Malignancy quite often complicates the course of chronic gastric ulcer, especially in case of long-lasting callous or penetrating ulcers. Clinically, this process is manifested by a change in the nature of pain, that becomes permanent, microhemorrhage (determined by the Gregersen reaction), distorted appetite, and increasing hypochromic anemia. With these symptoms, special research methods are required. However, even negative findings of these methods in the presence of strong clinical data in favor of malignant degeneration require immediate surgery.

In addition to absolute indications for surgery, there are also relative ones. A delay in intervention in these cases does not always lead to the death of the patient, but significantly complicates the course of the process and often entails additional complications that aggravate the patient's condition. Among the relative indications, the following ones are distinguished:

- 1) callous ulcers;
- 2) penetrating ulcers;
- 3) recurrent gastrointestinal bleeding, especially in a hospital;
- 4) failure of conservative treatment for 2–3 years.

Callous ulcers (usually gastric ones) are very difficult to treat conservatively, since the dense, callous edges of a long-lasting ulcer prevent ulcer epithelization, and epithelial metaplasia contributes to its malignant degeneration.

Penetrating ulcer develops when a peptic ulcer penetrates into adjacent organs, such as the liver, pancreas, and hepatoduodenal ligament, and causes significant persistent pain and dysfunction of the organs into which the ulcer penetrates. Healing of such ulcers under the effect of conservative treatment is very problematic, and successful surgical intervention allows to resolve the difficult situation.

Recurrent bleeding, especially in the hospital setting, is a good indication for surgery for the following reasons. Firstly, every recurrent bleeding, even a minor one, can at any time recur or turn into severe 3 bleeding, which directly threatens the patient's life. Secondly, recurrent bleeding leads to the development of posthemorrhagic anemia, in which the surgical intervention is significantly complicated due to the risk of posthemorrhagic complications. The surgical tactics for recurrent bleeding was developed by B.S. Rozanov and A.A. Rusanov, who claimed that every bleeding ulcer should be treated surgically on the first day after manifestations.

Many surgeons including the authors of this book refer *failure of conservative treatment* to indications for surgical treatment. Conservative treatment, unfortunately, does not always cure the patient (especially with duodenal ulcers). It contributes to a more or less prolonged remission with subsequent relapse of the disease. This is especially often observed if the patient after the course of treatment remains in the same conditions of life, work, nutrition, etc. In such cases, the duration of remission becomes short-term, and the exacerbation of the process is natural.

Surgeons often have to deal with patients who have had peptic ulcer for years and even decades. These people are constantly suffering from pain, they are forced to limit themselves in nutrition and often lose their working capacity due to frequent exacerbations of the disease. At the same time, reasonable surgical intervention can restore their health and performance. Therefore, most surgeons believe that the failure of conservative treatment of ulcers for 2–3 years, especially if during this period the patient underwent courses of anti-ulcer therapy in hospital, is an indication for surgical treatment.

Currently, surgery for peptic ulcer is carried out under modern anesthesia. Still, any intervention in this pathology can be performed under local and spinal anesthesia. The advantages of anesthesia in this situation include not only painlessness of the operation, but also muscle relaxation, which greatly eases surgeon's actions, as well as the ability to control vital body functions during modern anesthesia, which is no less important for a severe patient.

At present, most surgeons distinguish two main forms of peptic ulcer — gastric ulcer and duodenal ulcer. This is probably explained by the nature and causes of formation of these types of pathology. According to G.K. Zherlov and G.E. Sokolovich, the key features of ulcerogenesis in gastric ulcers are impaired barrier functions of the gastric mucosa (reduced protective properties of mucus and regenerative ability of the epithelium, impaired blood flow and metabolism), changes in the motor and evacuation functions of the stomach and damage to the mucous membrane by harmful substances (nicotine, ethyl alcohol, helicobacteriosis, etc.).

With duodenal ulcers, ulcerogenesis mainly depends on the level of secretion of gastric juice, a decrease in the ability to neutralize gastric juice, and a decrease in the resistance of the intestinal mucosa to helicobacter. With this localization of the ulcer, stressful situations, especially recurring ones, play an important role in the development of the pathological process.

The ratio of men and women among patients with gastric ulcers is 3:1, and among patients with duodenal ulcers — 4:1 (Yudin, 1955; Pantsyrev, 1973).

Many surgeons insist on the individual selection of the type of surgical intervention for various ulcer localizations (Lytkin, 1998; Pantsyrev, 1973; Chernousov, 1996). However, there are generally accepted provisions, the knowledge of which will help the surgeon to choose the most optimal method of surgical treatment for peptic ulcer disease.

Currently, the following methods exist for surgical treatment of ulcers:

- 1) ulcer suturing;
- 2) ulcer stitching;
- 3) gastric resection;
- 4) operations on the vagus nerves:
 - truncal vagotomy;
 - selective vagotomy (SV);
 - selective proximal vagotomy (SPV);
 - selective proximal vagotomy in combination with sparing gastric resection.

Ulcer suturing is an operation that is performed only with perforated ulcer of the stomach or duodenum.

The first such intervention was carried out by Johann Mikulicz on October 7, 1880.

Usually suturing a perforated ulcer is a fairly simple operation. After laparotomy and examination, a perforation site is found and sutured with interrupted stitches in two tiers. The line of sutures can be covered with a pedicled omental flap. After cleaning, the abdominal cavity is sutured tightly or with a micro-irrigator. In case of perforation of a large callous ulcer, the ulcer should be sutured according to the Oppel–Polikarpov's technique: taking a lock of the greater omentum on the needle and puncturing the stomach wall from the side of the perforation. This manipulation

is repeated twice with both ends of the thread. When tying the thread, the omentum clogs the perforation. Additionally several interrupted sutures are made, fixing the omentum to the stomach wall. In recent years, with the development of endosurgery for perforated ulcers, the perforation has been sutured during laparoscopy (V.P. Sazhin).

Mortality after suturing the ulcer is low and mainly depends on the timing of the operation: a few hours after perforation, it amounts to second decimal places of a percent, and after a day or more — to 80%. According to D.F. Skripnichenko, operations performed in the first 6 hours after perforation give a mortality rate of 1–2%, and operations performed after 24 hours — 30%; according to V.S. Savelyev, in 1972 mortality in the Soviet Union amounted to 5.3%; according to V.D. Fedorov, in Russia in 2013, it reached 8.9%.

Ulcer suturing is extremely simple technically and can be carried out in almost any environment (district hospital, field conditions). With timely surgery in the first hours after perforation, the intervention is not lethal and saves the patient's life.

The disadvantage of the operation is that it does not eliminate factors causing ulcer formation. Therefore, the percentage of relapses after ulcer suturing is quite large (according to various authors, up to 67%). Thus, ulcer suturing saves the patient's life, but does not cure a peptic ulcer. Cases of recurrent perforations of ulcers (up to 5 times) after suturing are known in literature.

Ulcer stitching is a rare operation that is used in exceptional cases when, with bleeding ulcer, the patient's condition is so severe that they are unable to withstand any other intervention, and other methods to stop bleeding (laser or non-contact coagulation during gastroscopy) are ineffective. This operation is performed for extremely severe elderly patients. After laparotomy, gastrotomy is performed, ulcer and a bleeding vessel in its bottom are found, and the vessel is stitched with pulley sutures. After this, the dissected wall of the stomach and the abdominal wall are sutured in two tiers.

The main operation currently used to treat peptic ulcer is gastric resection. The first resection of the stomach in a cancer patient was performed by the French surgeon Jules-Emile Pean on April 9, 1879. The patient died on the 4th day after the operation. The first successful resection of the stomach with cancer lesion was carried out in Vienna by Theodor Billroth on January 29, 1881. A 38-year-old patient recovered after the operation. After surgery, Billroth connected the gastric remnant with the duodenum with end-to-end anastomosis. On January 15, 1885, during a resection, Billroth, having failed to connect the gastric remnant to the duodenum, sutured the latter, and connected the stomach to the jejunum loop with end-to-side anastomosis. The former operation was called “Billroth I gastric resection”, and the latter — “Billroth II gastric resection”. Each of these operations has up to 30 modifications, but the principle (the connection of the gastric remnant with the intestine) remains the same. The first intervention is carried out almost according to the Billroth's method; the difference lies in the fact that the gastric remnant is sutured from the side of lesser curvature. The second modification is often carried out according to the method of Hofmeister–Finsterer or Hacker–Savinykh, when a part of the stomach remnant on the side of the lesser curvature is sutured, and the remnant is connected with the initial section of the jejunum with end-to-side anastomosis.

For peptic ulcer, the first successful gastric resection was carried out in Vienna by Riediger on November 21, 1881. In Russia, the same operation for peptic ulcer was performed by M.K. Kitaevsky on June 16, 1881. The main principles of gastrectomy for peptic ulcer were formulated by S.S. Yudin more than 50 years ago and remain effective to the present day. S.S. Yudin determined the conditions under which the ulcer should be removed, and gastric secretion should be suppressed as a result of the operation.

1. During the operation, it is necessary to remove the acid-producing zone of the stomach; it accounts for almost 2/3 of the organ, with very high acidity it occupies 3/4 of the stomach.
2. It is necessary to remove the zones producing gastrin (prosecretin), i.e., remove the antrum and the pyloric section of the stomach and the first section (up to 2 cm) of the duodenum.
3. Along the resection line, it is necessary to transect the fibers of the vagus nerve (almost from the esophagus).

Thus, a radical effect is exerted on the first (reflex) and second (hormonal) phases of gastric secretion, the zone producing gastric juice is reduced, and conditions favorable for formation of ulcers in the remaining sections of the stomach are eliminated.

The operation of gastric resection with peptic ulcer in most hospitals is performed according to these principles. In the Surgical Clinic of Siberian State Medical University, gastric resection with gastric ulcers and, when it is technically possible, with duodenal ulcers is performed according to the Billroth I technique. The part of gastric remnant from the side of lesser curvature is sutured and placed in the lumen of the organ, and its remaining part is connected to the duodenum with end-to-end anastomosis (Fig. 2.1). With duodenal ulcers with significant changes in the initial part of the intestine and with penetrated duodenal ulcers, the stomach is resected according to the Billroth II method in the modification by Hofmeister–Finsterer, which consists in the fact that after removing a part of the stomach and transecting the duodenum, a part of the gastric remnant from the side of the lesser curvature is sutured and placed in the lumen of the stomach in the form of a keel. The duodenal remnant is sutured in the usual or atypical way blindly. The gastric remnant is connected to the first section of the jejunum with end-to-side anastomosis. Typically, this anastomosis is placed behind the transverse colon through its mesentery (Fig. 2.2).

With difficulties in suturing the stump of the duodenum, a number of methods are used: the Yudin's method, when the remnant of the duodenum is closed in the form of a snail, or Krivosheev's method, when the sutured duodenal remnant is submerged in a purse string suture in the form of a submersible hood.

The advantages of gastric resection surgery include persistent and long-term cure of the patient. If the operation is performed according to strict indications with strict observance of the above described rules, then good and satisfactory outcomes after this operation are observed in over 90% of cases (A.G. Savinykh, S.S. Yudin), and unsatisfactory ones — only in 5% of cases. Mortality rate after planned resections of the stomach is from 2 to 5% (S.S. Yudin, V.S. Mayat, A.A. Grinberg). In the Savinykh Surgical Clinic, after 1,000 operations by 1963, mortality had been equal to zero.

Disadvantages of gastric resection are the following; the operation is quite complicated and requires scrupulous performance of all the steps. It must be carried out by a highly qualified surgeon. For the successful operation, certain conditions

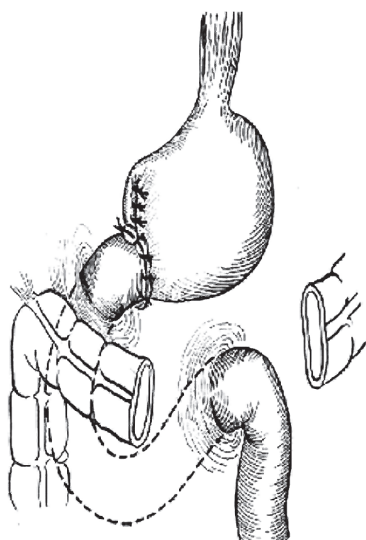


Fig. 2.1. Billroth I gastric resection

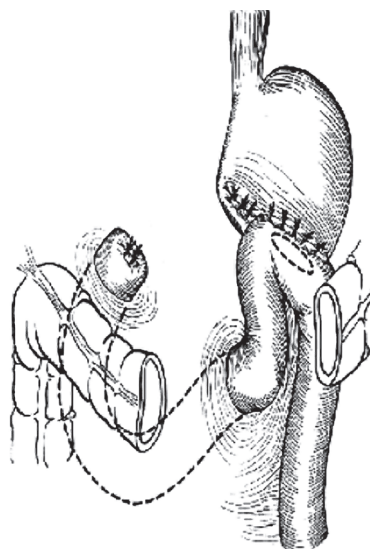


Fig. 2.2. Billroth II gastric resection in the modification by Hofmeister-Finsterer

are required: the presence of a sufficiently equipped operating room, a qualified anesthesiologist, an experienced assistant and sufficient blood bank. The operation cannot be performed in conditions of peritonitis with perforated ulcer and in cases of severe anemia with bleeding ulcer.

If the operation is planned, then a test for dumping syndrome should be done before it: the patient is injected with glucose into the stomach through a tube, and then the blood sugar level and the patient's condition are monitored. If there are signs of dumping, it is advisable to perform a resection according to the Billroth I technique, since it is more physiological. To prevent reflux gastritis, it is advisable to perform an operation according to Roux method, when the remnant of the stomach after suturing on the side of the lesser curvature is connected to the jejunum and mobilized according to Roux technique with end-to-side anastomosis, and the remnant of the duodenum is sutured blindly. Recently, in the surgery of gastric and duodenal ulcers, pylorus-modeling resections in combination with valve constructs have been used to prevent the reflux of the duodenal or intestinal contents in the stomach remnant (G.K. Zherlov et al., 2000).

In 1947, Dragstedt published the results of bilateral subphrenic vagotomy for treatment of a complicated duodenal ulcer (Fig. 2.3). The aim of the operation was to turn off the first reflex phase of gastric secretion to heal a duodenal ulcer with a high level of acidity. The ulcer healed. Based on the materials of Dragstedt and his predecessors who performed partial transections of the vagus nerves, many surgeons began to perform such operations with duodenal ulcers. It turned out that after such interventions, patients, despite healing of the ulcer, developed severe complications in the form of persistent spasm of the pylorus and various disorders of the liver, pancreas, and intestines, since these organs are also innervated by the

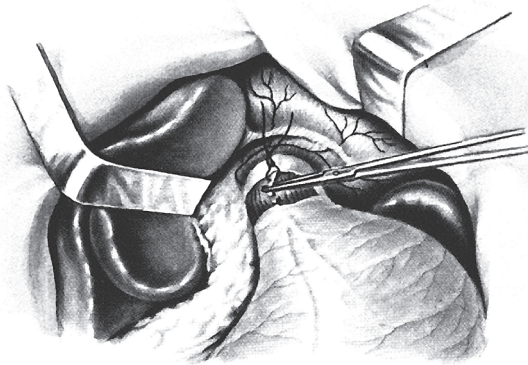


Fig. 2.3. Truncal vagotomy

vagus nerves. In this regard, in order to eliminate persistent spasm of the pylorus, Dragstedt, in addition to truncal vagotomy, performed gastric drainage operations in the form of pyloroplasty or gastroenterostomy (Fig. 2.4). The same operations started to be used in emergency cases after suturing perforated duodenal ulcers

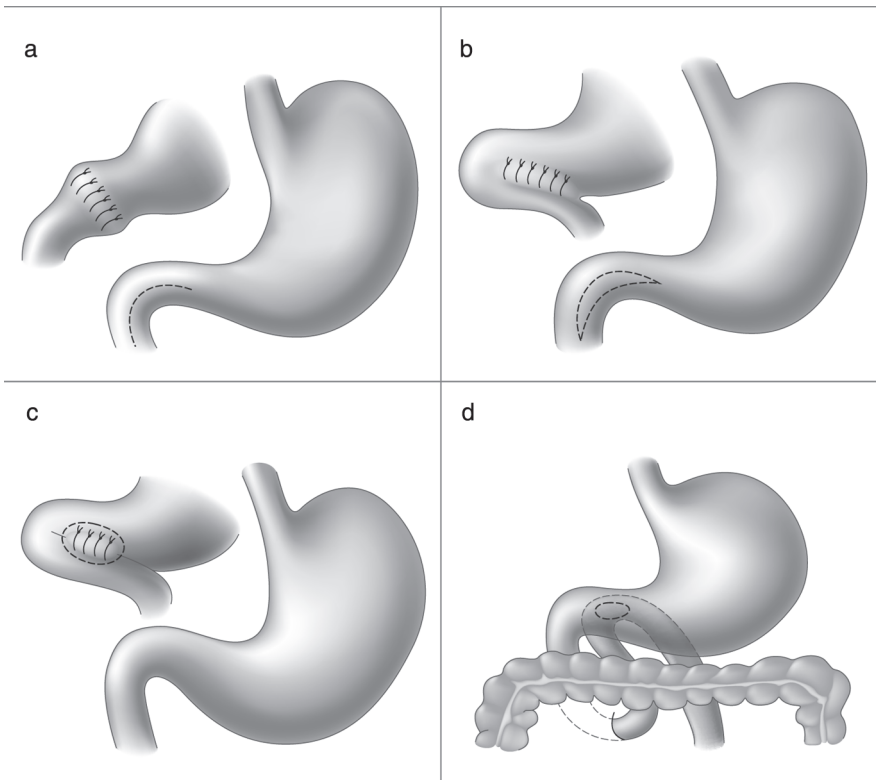


Fig. 2.4. Gastric drainage operations: a — pyloroplasty by Heineke–Mikulicz; b — pyloroplasty by Finney; c — gastroenterostomy by Zhabuliy; d — gastroenteroanastomosis

(A.I. Krakovsky, Yu.M. Pantsyrev, etc.). Such interventions are currently rare. At the XXIV International Congress of Surgeons in Moscow, Dragstedt announced that he was a student of the Russian scientist I.P. Pavlov and based his conclusions on the results of his work, as well as 2,000 operations on animals to study various variants of vagotomy. At the same congress, he spoke in favor of bilateral selective vagotomy proposed by Franksson in 1948, during which only branches of the vagus nerve going to the stomach are transected. In this case, the nerve of Latarjet should be spared, which is in charge of parasympathetic innervation of the solar plexus elements, i.e., innervation of the liver and pancreas (Fig. 2.5).

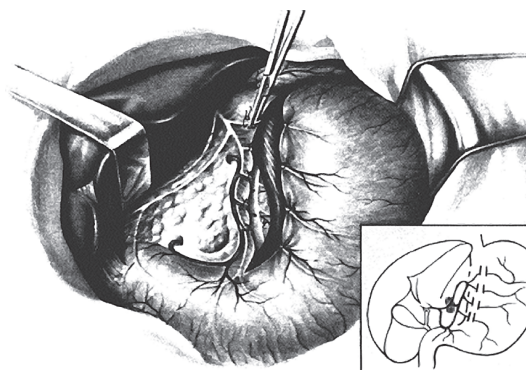


Fig. 2.5. Selective vagotomy

Advantages of truncal vagotomy are the following: the operation is technically quite simple, provides a high therapeutic effect, and almost does not cause mortality, i.e., duodenal ulcers with high acidity heal in most cases after surgery. The disadvantages of the operation are the presence of persistent spasm of the pylorus and significant disorders of the liver, pancreas, and intestinal motility in all cases, which makes the patients' visit the surgeon constantly. If the vagotomy is not fully implemented, the ulcer does not heal and all complications of the disease may develop. This operation should be always supplemented with gastric drainage operations — pyloroplasty or gastroenteroanastomosis.

Selective vagotomy. The advantages of the operation are that the ulcer heals in 80–90% of cases. The stomach is preserved. Mortality rate after it is significantly lower than after gastric resection. Disadvantages of the operation are in complexity of execution, which include careful preparation of the vagus nerve branches and the need to perform stomach-draining pyloroplasty or gastroenterostomy like after truncal vagotomy. In addition, during an inadequate operation, when separate branches of the vagus nerve remain untransected, the ulcer does not heal and the frequency of development of anastomotic ulcers remains high. According to various authors, it ranges from 6 to 19% (A.A. Kurygin, Yu.M. Pantsyrev, A.A. Grinberg).

Hart and Holle (1966, 1968) proposed *selective proximal vagotomy* (SPV), during which only the vagus nerve branches leading to the acid-producing zone of the stomach are transected and which spares Latarjet's nerve and vagus nerve branches going to the pylorus (Fig. 2.6).

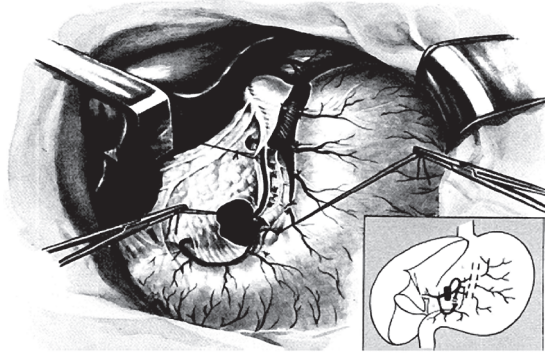


Fig. 2.6. Selective proximal vagotomy

Advantages of selective proximal vagotomy (SPV) are the following: low mortality rate; the ulcer heals; the stomach is preserved; and there is no need for gastric drainage.

The disadvantages of SPV are technical complexity — it is more complicated than gastric resection (in time and technique of implementation); if the transection of the vagus branches is incomplete due to technical errors or development options, the ulcer does not heal, all complications of the disease and peptic ulcers may develop, complicating the already serious condition of the patient.

In connection with the listed disadvantages of selective vagotomy (SV) and selective proximal vagotomy (SPV), Holle (1968) and V.S. Savelyev (1980) suggested combining SPV with sparing gastric resection. This intervention was recommended by V.S. Savelyev and Yu.M. Pantsyrev at the XXX All-Union Congress of Surgeons as the operation of choice for complicated duodenal ulcers: after selective proximal vagotomy, the stomach is resected, but not 2/3 as usual, but an antrumectomy is performed when the antrum with the ulcer and the first section the duodenum are resected (Fig. 2.7). Vagotomy turns off the first phase of gastric secretion, and antrumectomy — the second. As a result, gastric secretion is suppressed and ulcer is removed.

Advantages of the operation are compliance with the rules recommended by S.S. Yudin, and preservation of most part of the stomach.

Disadvantages of the operation include the difficulty of performing selective proximal vagotomy and the duration of the intervention.

When performing operations on the vagus nerves, the following points should be taken into account: the mandatory study of all phases of gastric secretion to determine the predominance of one of them. With high acidity and duodenal ulcers, vagotomy reduces the production of hydrochloric acid by about 55%. In this regard, the SPV operation is effective only in cases where the basal acid output (BAO) does not exceed 10 mEq/h, and stimulated acid output is 40 mEq/h (Yu.M. Pantsyrev, A.A. Greenberg). When BAO is 10–20 mEq/h and stimulated one is 41–45 mEq/h, the surgeon should resort to SPV in combination with antrumectomy (sparing resection of the stomach). In cases when BAO reaches 15 mEq/h and stimulated acid output is 45 mEq/h, a typical gastrectomy should be performed (G.E. Sokolovich, G.K. Zherlov).

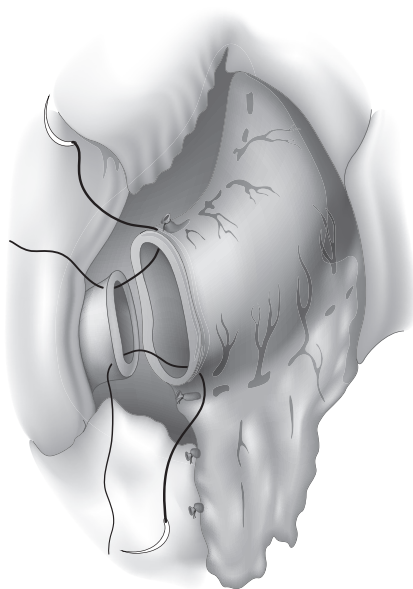


Fig. 2.7. Selective proximal vagotomy with sparing gastric resection

Yu.M. Pantsyrev believes that the outcome of a surgical intervention, the mortality rate, and the patient's health largely depend on the skill of the surgeon in each case to choose an operation adequate for the patient.

Assessing the overall surgical treatment of peptic ulcer, it should be said that the successful outcome of the operation depends on strict adherence to the indications for surgical intervention: for perforated ulcers, this is suturing of the ulcer and resection of the stomach in the cases indicated; in extremely severe patients, as a last resort during bleeding, ulcer stitching should be performed. In most cases, a typical gastric resection is indicated as a well-thought operation that gives good outcomes. In cases of complicated duodenal ulcers with high secretion level in the first phase of gastric secretion, selective proximal vagotomy or SPV combined with antrumectomy (sparing resection of the stomach) should be opted for. Compliance with these rules results in good immediate and long-term outcomes and brings patients back to work.

Surgical treatment of patients with peptic ulcer disease is best carried out in the hospital setting by surgeons with experience in such interventions, especially in surgeries on duodenal ulcers, when a careful choice of surgery technique is required depending on the type and level of gastric secretion.

PERFORATED ULCER OF THE STOMACH AND DUODENUM (*ULCUS PERFORANS*)

Perforated ulcers of the stomach and duodenum belong to the most severe and dangerous complications of peptic ulcer. Among acute diseases of the abdominal organs, they account for up to 1.2–1.5% (according to certain authors, up to 3.2–5.4%).